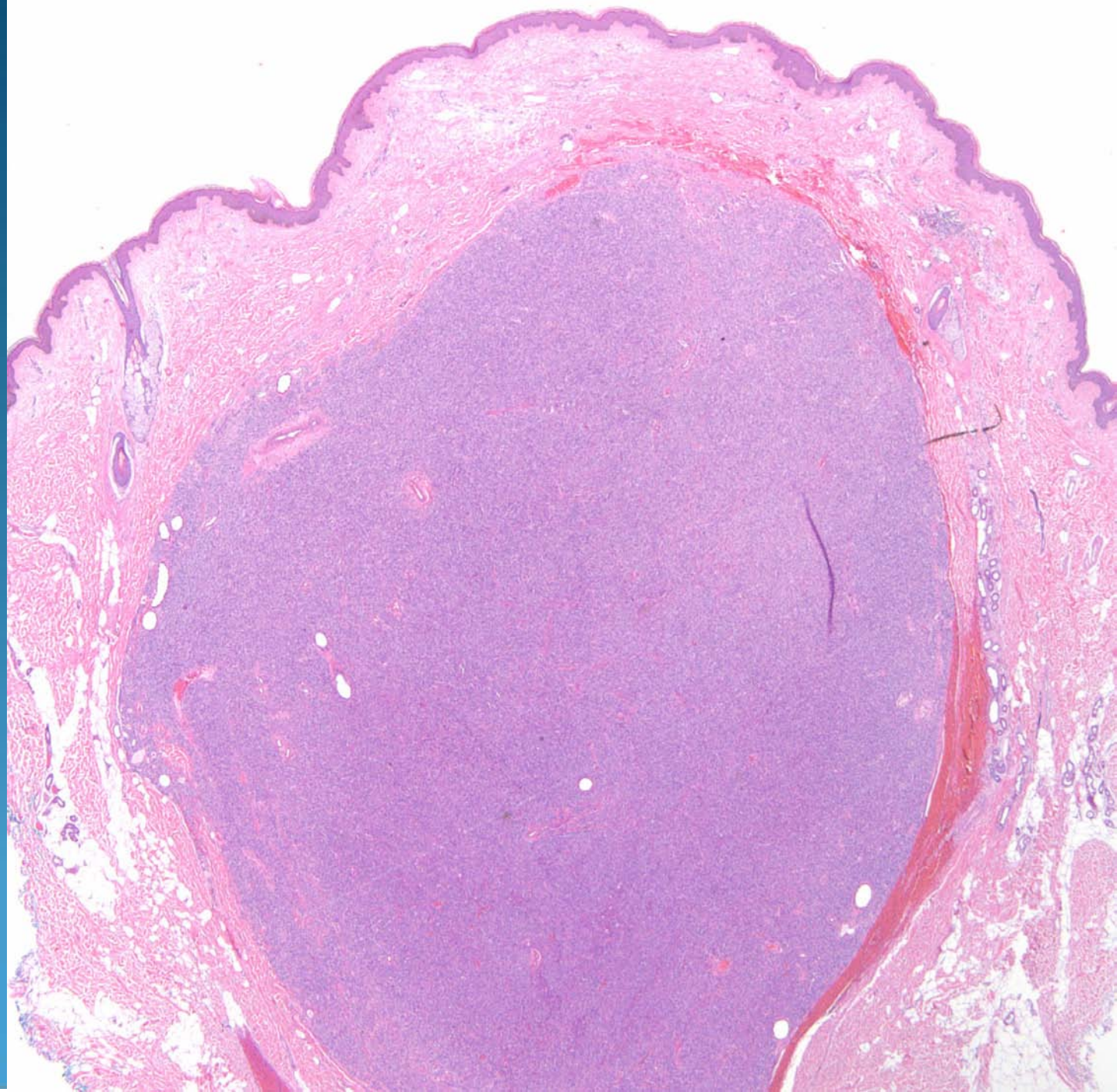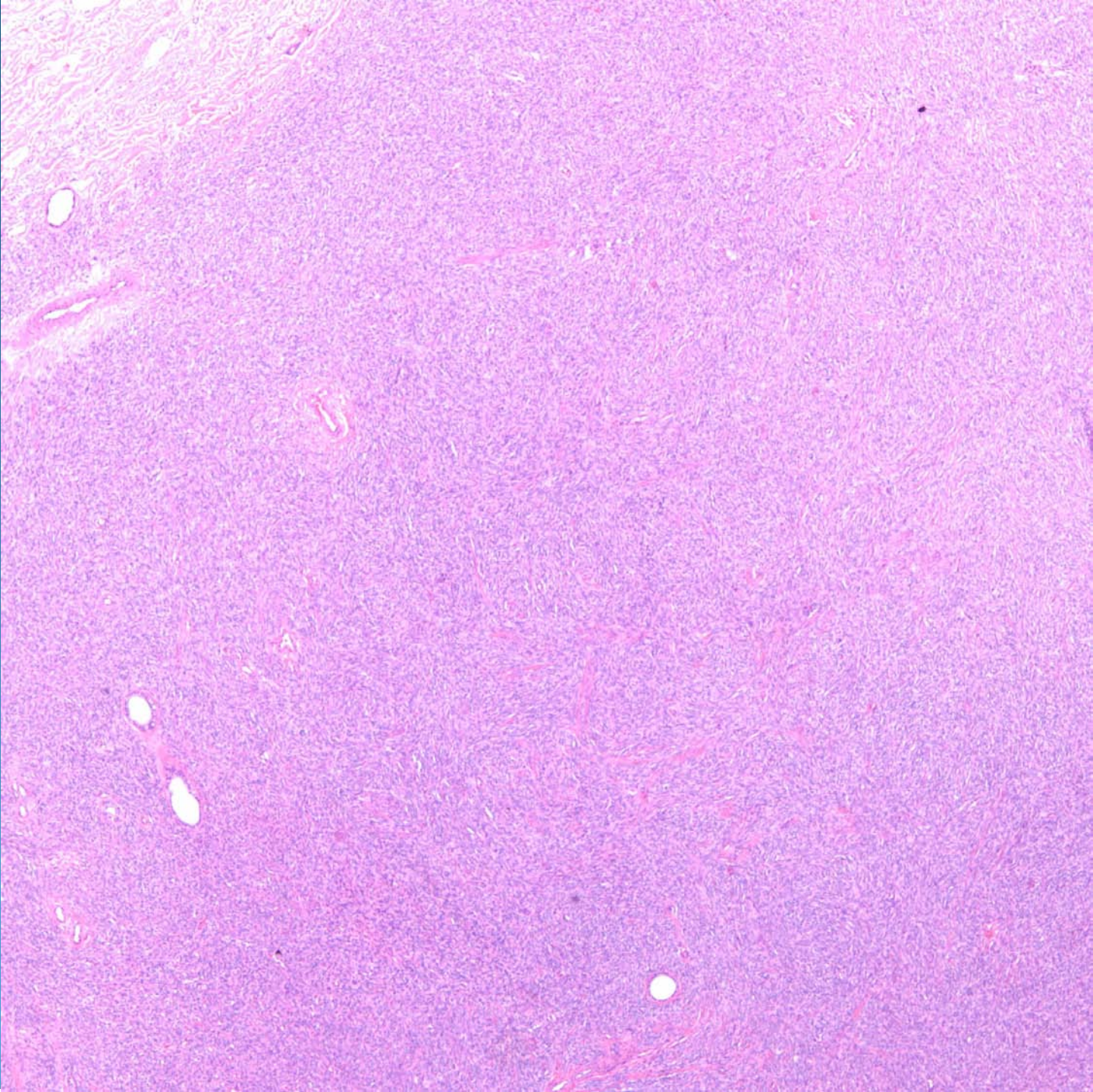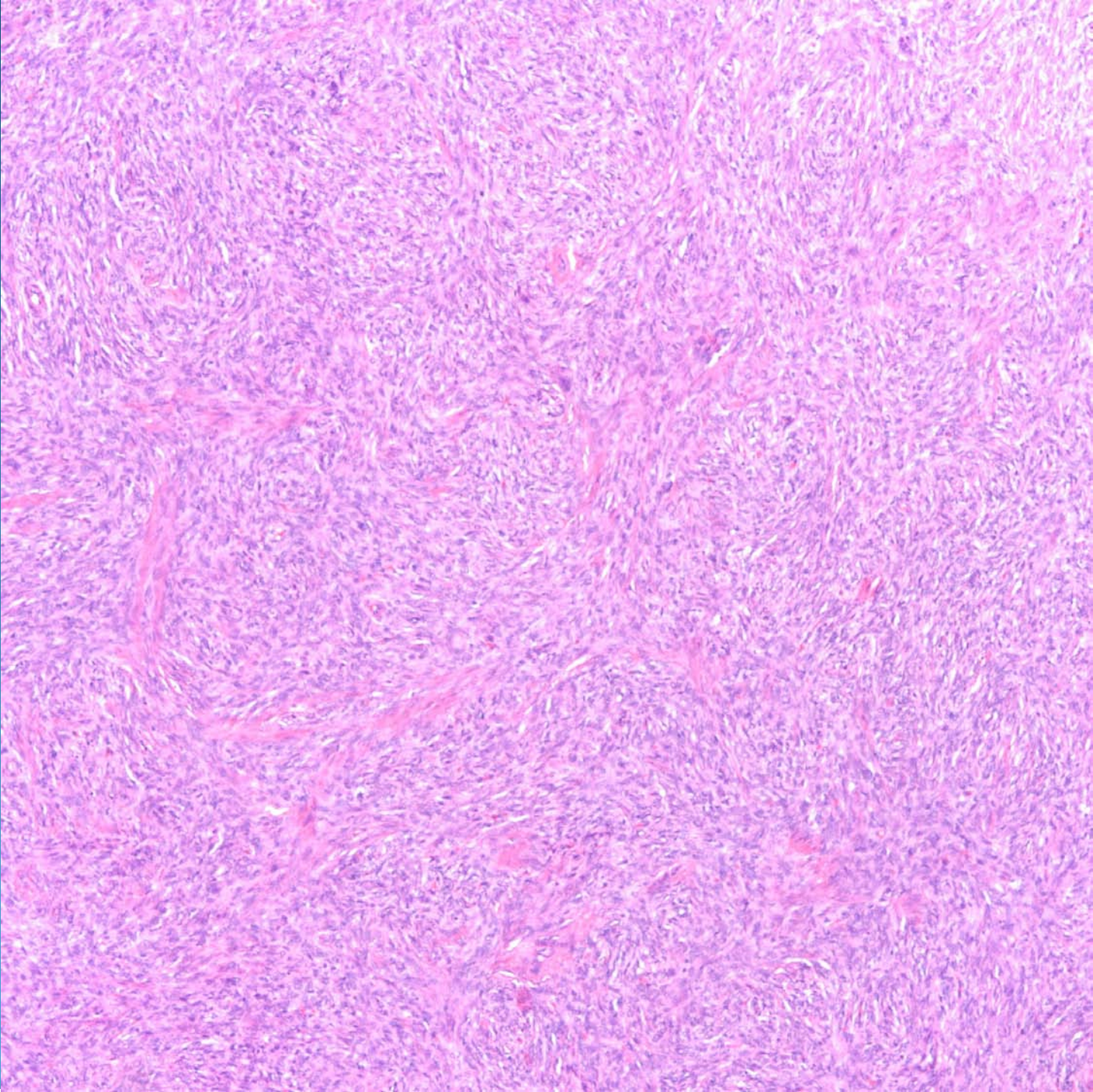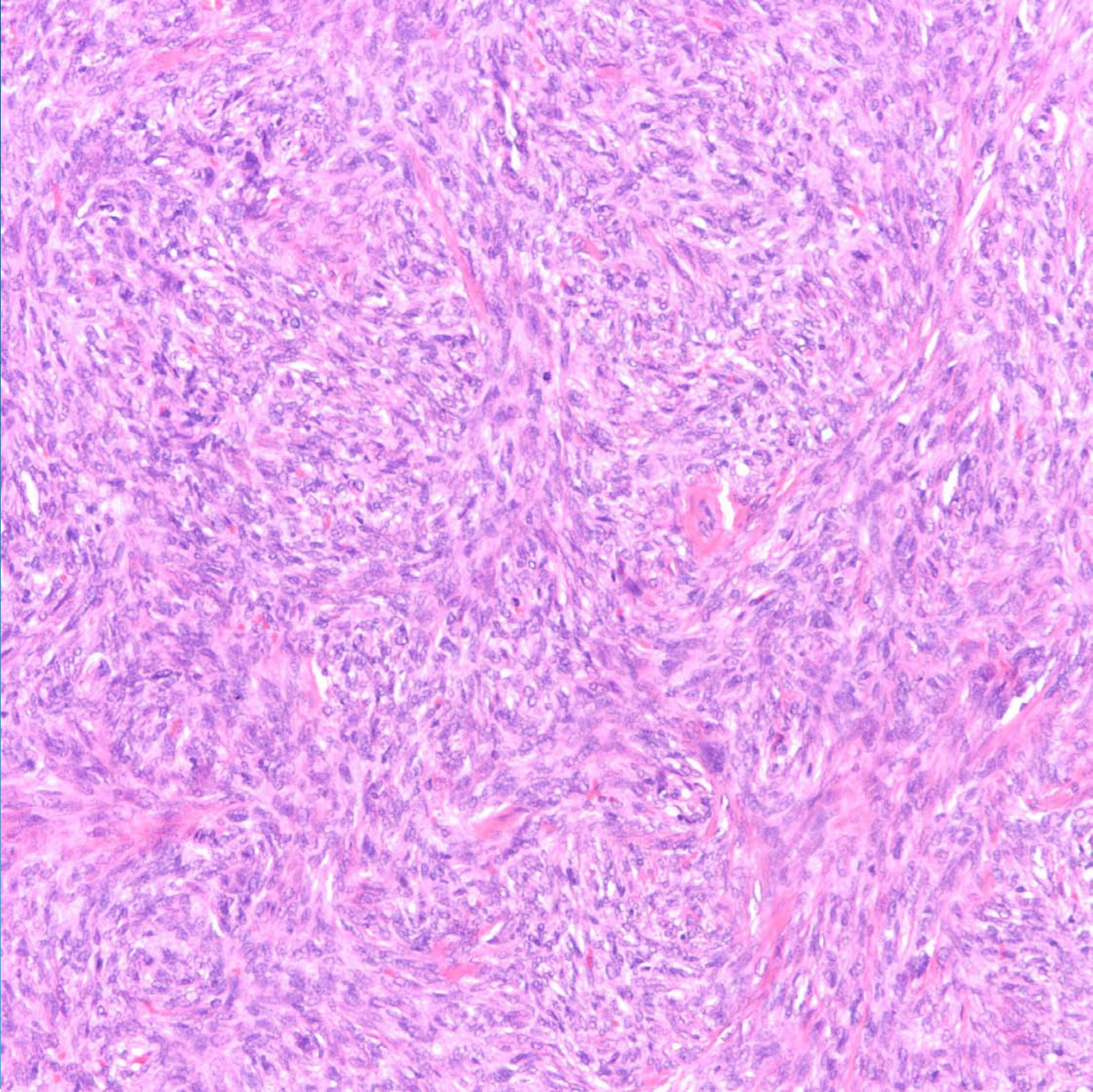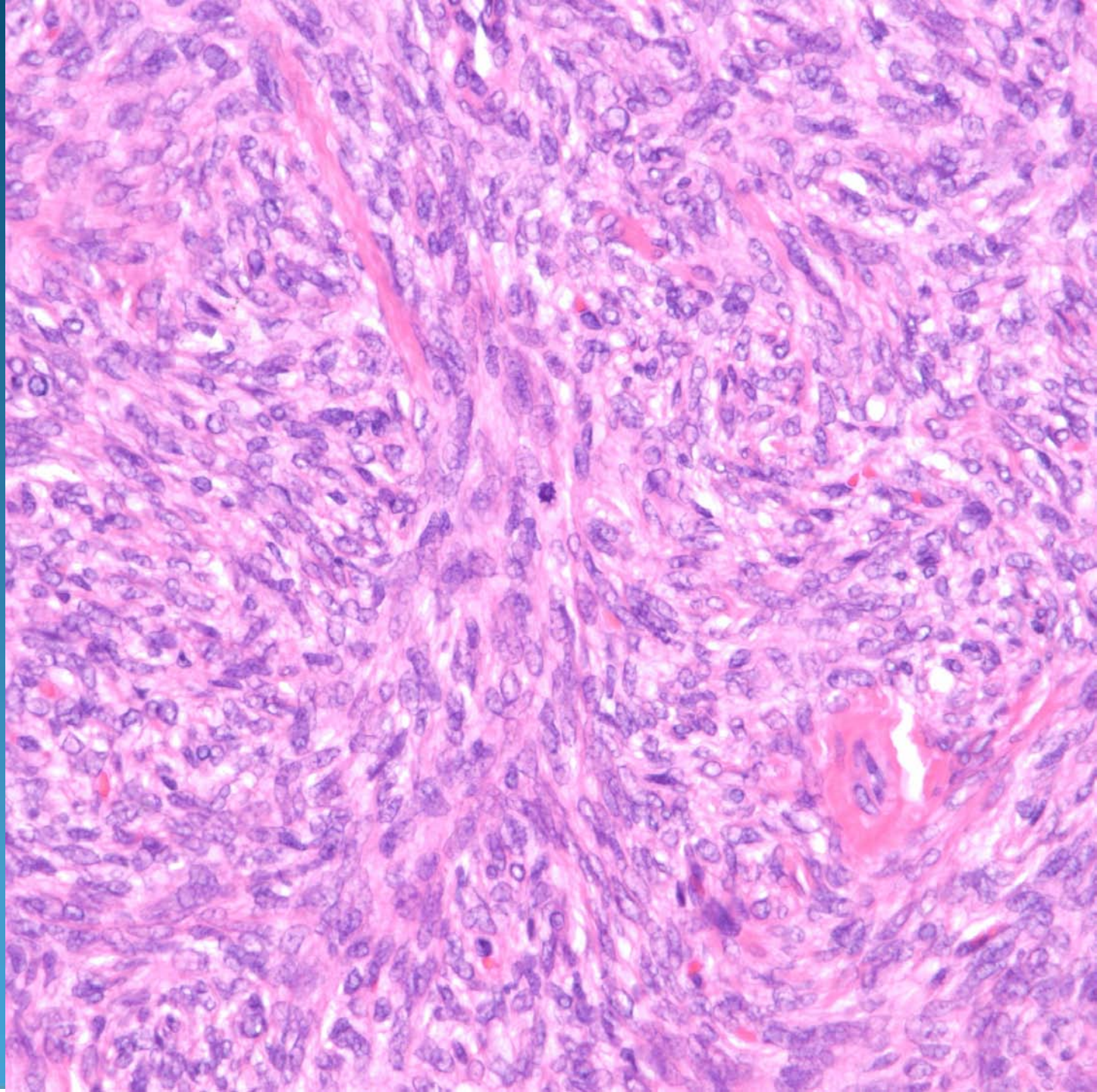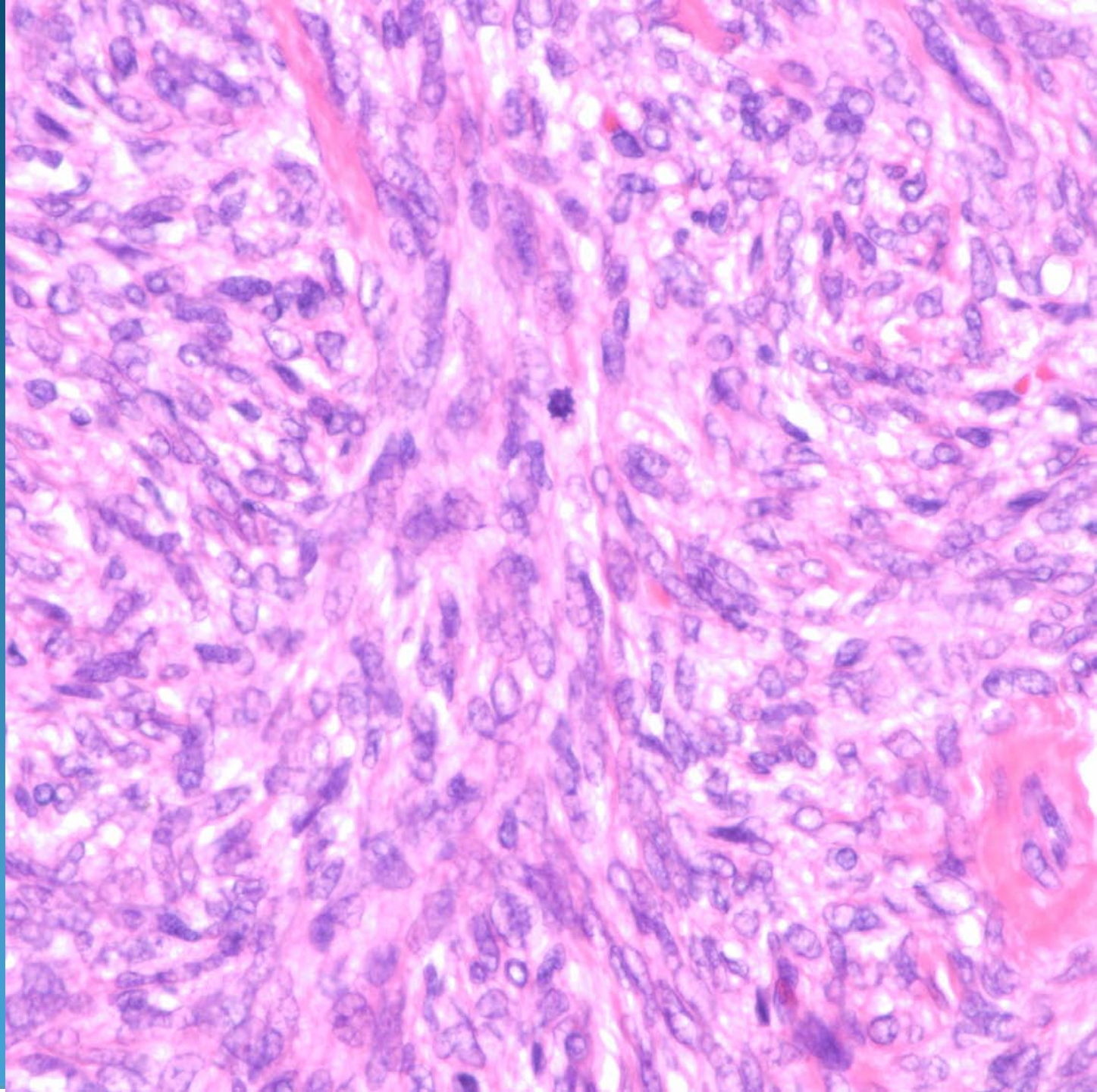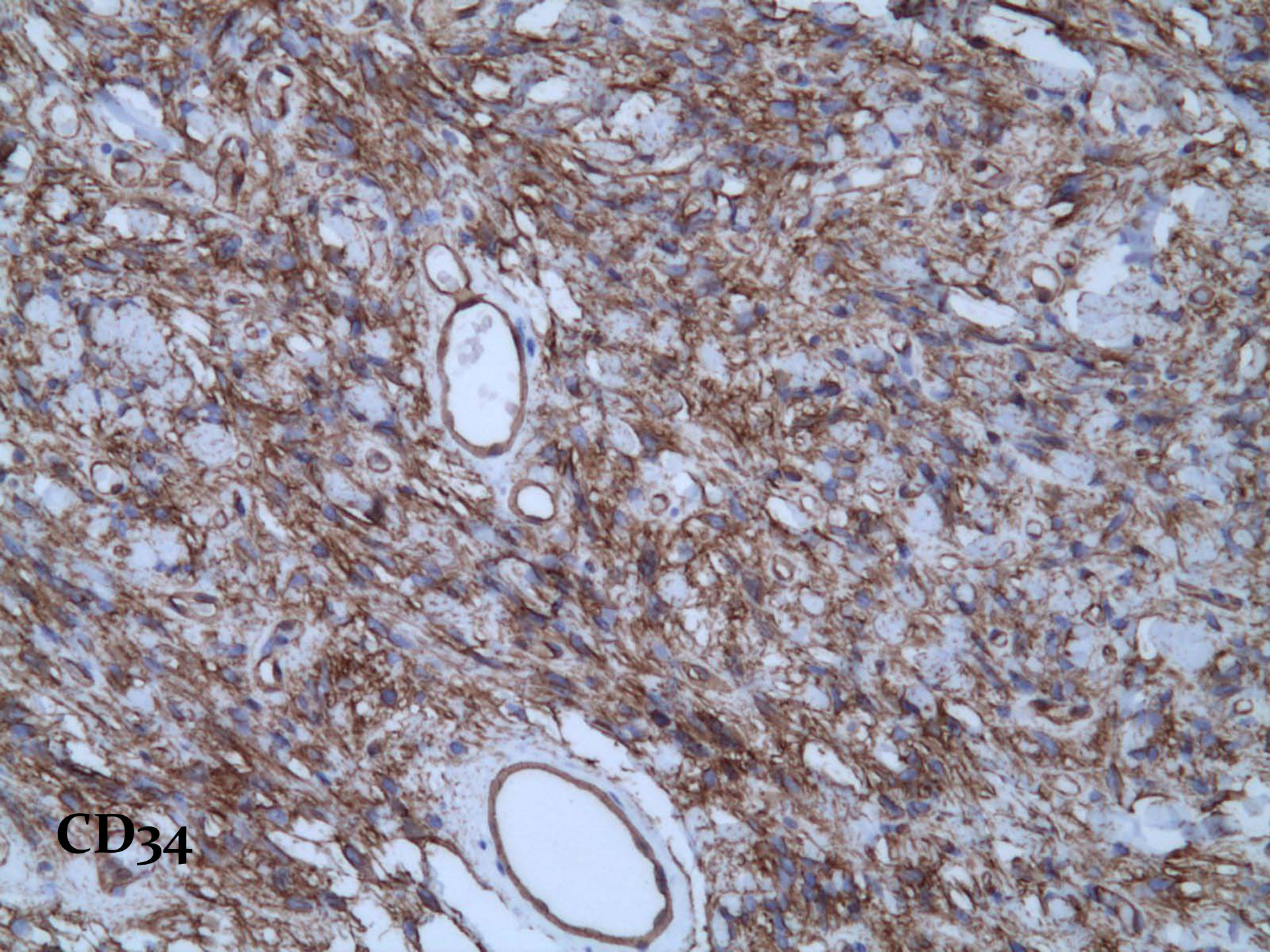
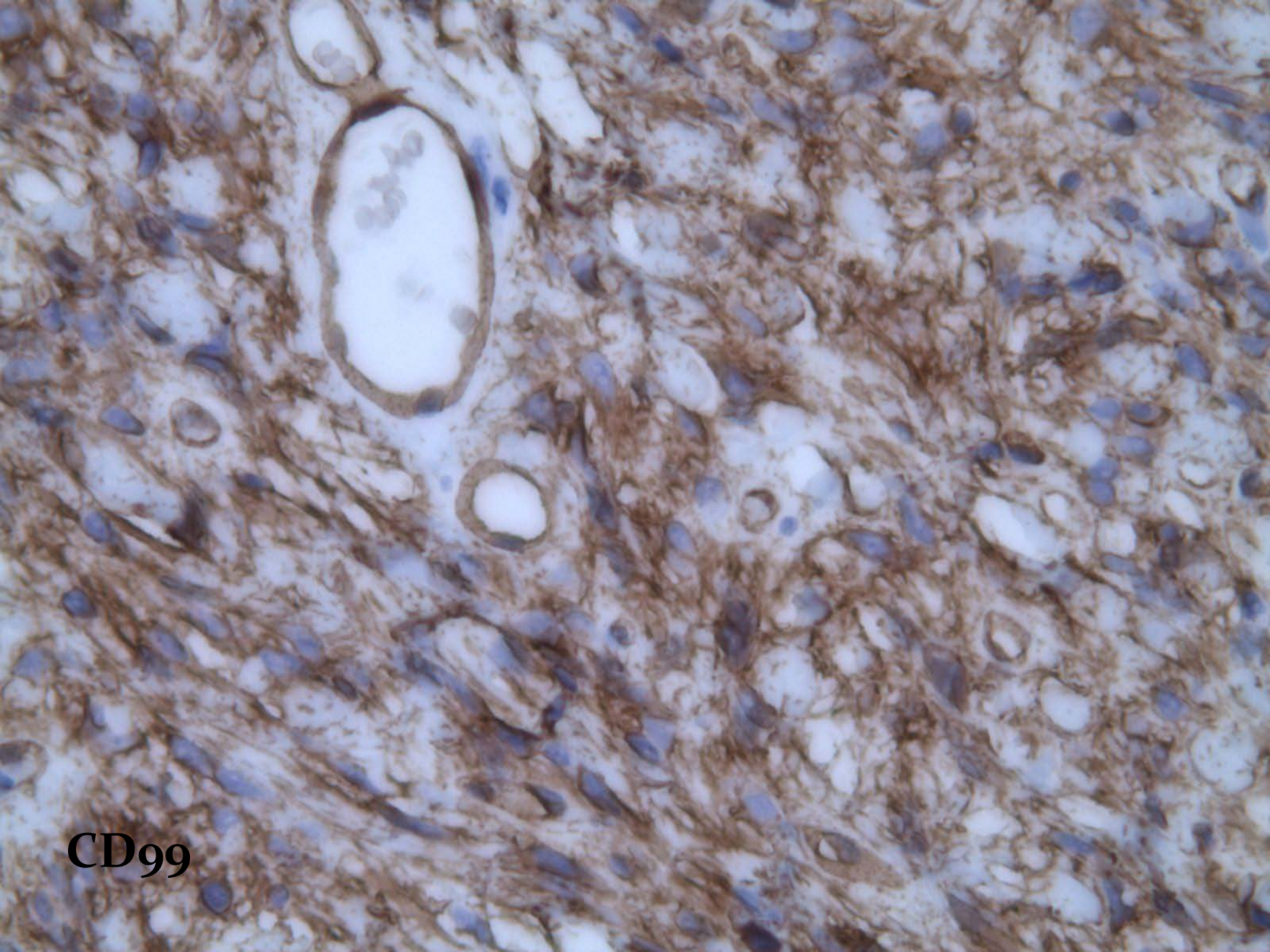


Solitary Fibrous Tumor

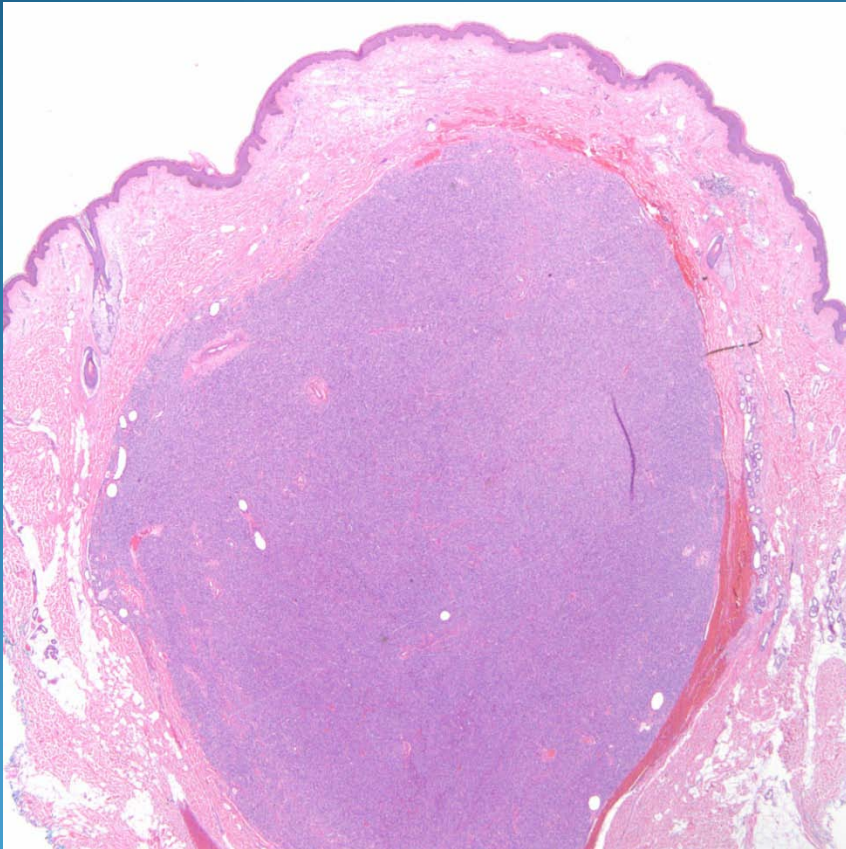


CD34



CD99

Pearls



- Cellular and circumscribed dermal tumor
- Variable vascularity
- In benign lesions, usually minimal atypia and MF<4 per 10hpf
- Overlap with hemangiopericytoma of the skin
- Confirm with IHC: CD34+